

Barrow Neurological Institute at St. Joseph's Hospital and Medical Center

## Barrow - St. Joseph's Scholarly Commons

---

Neurology

---

2011

### Bilateral Vestibular Hypofunction in Neurosarcoidosis: A Case Report

Jonathan H. Smith

Kyndra C. Stovall

Stephen W Coons  
stephen.coons@dignityhealth.org

Terry D. Fife  
*Barrow Neurological Institute*, tfife@email.arizona.edu

Follow this and additional works at: <https://scholar.barrowneuro.org/neurology>

---

#### Recommended Citation

Smith, Jonathan H.; Stovall, Kyndra C.; Coons, Stephen W; and Fife, Terry D., "Bilateral Vestibular Hypofunction in Neurosarcoidosis: A Case Report" (2011). *Neurology*. 56.  
<https://scholar.barrowneuro.org/neurology/56>

This Article is brought to you for free and open access by Barrow - St. Joseph's Scholarly Commons. It has been accepted for inclusion in Neurology by an authorized administrator of Barrow - St. Joseph's Scholarly Commons. For more information, please contact [suefue.espe@commonspirit.org](mailto:suefue.espe@commonspirit.org).

# Bilateral vestibular hypofunction in neurosarcoidosis: A case report

Jonathan H. Smith, MD; Kyndra C. Stovall, PhD; Stephen Coons, MD;  
Terry Douglas Fife, MD

## Abstract

*We describe the case of a 59-year-old woman who presented with progressive bilateral vestibular hypofunction and who was found to have bilateral granulomatous mass lesions of the mesial temporal lobe. Initially, her condition stabilized neurologically with corticosteroids, but a diagnosis of neurosarcoidosis was delayed because of the unusual presentation and persistently normal chest imaging results and serum angiotensin-converting enzyme (ACE) levels. Approximately 1 year after her initial presentation, the patient died of complications of a myocardial infarction and pulmonary embolism. Sarcoidosis should be considered in the differential diagnosis of idiopathic bilateral vestibular hypofunction even if the chest imaging and serum ACE levels are normal, particularly when there is evidence of a multisystem process.*

## Introduction

Sarcoidosis is a chronic multisystem granulomatous disorder of unclear etiology. Pathologically, it features diseased tissue that is characterized by the presence of epithelioid, noncaseating granulomas. Neurosarcoidosis is a rare manifestation of this disease, clinically affecting only 5% of all patients with sarcoidosis.<sup>1</sup> The most common neurologic feature of neurosarcoidosis is cranial neuropathy, which is attributable to frequent granulomatous involvement of the basal leptomeninges. Parenchymatous disease may also occur, most often in the hypothalamus and the pituitary gland.<sup>2</sup>

Audiovestibular dysfunction in neurosarcoidosis is rare. In an extensive review of neurosarcoidosis case

reports, Colvin found that 28 of 31 patients (90%) for whom audiometric data were available had experienced either a sudden or rapidly progressive hearing loss.<sup>3</sup> Among 24 patients who had undergone vestibular function testing, 23 had abnormal results; of these 23, 6 had unilateral and 16 had bilateral loss of vestibular function (the remaining patient's study was nonlocalizing). Vestibular impairment in the absence of hearing loss may also occur.<sup>4</sup>

In this article, we describe an unusual case of neurosarcoidosis that featured the rare manifestation of bilateral vestibular dysfunction in the absence of auditory impairment.

## Case report

A 59-year-old woman presented with a 4-month history of progressive gait imbalance without vertigo. Examination showed a widened gait base and poor balance. Hearing, speech, articulation, and vision were normal. Magnetic resonance imaging (MRI) of the brain demonstrated an increased signal on gadolinium-enhanced T1-weighted imaging in the mesial right temporal lobe and minimal change in the left temporal lobe (figure 1, A). A diagnosis of herpes simplex encephalitis was entertained along with other infectious, inflammatory, and neoplastic etiologies. Cerebrospinal fluid (CSF) studies revealed 14 white blood cells/ $\mu$ l, which were 100% lymphocytes; a CSF glucose level of 57 mg/dl; and a CSF protein concentration of 52 mg/dl. Bacterial and fungal cultures were negative, as was a polymerase chain reaction assay for herpes simplex in CSF. In addition, findings on CSF VDRL testing, coccidioides serology, cerebral angiography, and chest x-ray were all normal. Electroencephalography (EEG) showed bitemporal slowing, but no epileptiform changes. The serum angiotensin-converting enzyme (ACE) level (17 U/L) and serum calcium concentration (9.7 mg/dl) were both within normal limits. A purified protein derivative of a

From the Department of Neurology, Mayo Clinic, Rochester, Minn. (Dr. Smith); the College of Pharmacy, University of Georgia, Athens (Dr. Stovall); and the Barrow Neurological Institute, University of Arizona College of Medicine, Phoenix (Dr. Coons and Dr. Fife).

Corresponding author: Terry Douglas Fife, MD, Barrow Neurological Institute, 240 W. Thomas Rd., Suite 301, Phoenix, AZ 85013. E-mail: [tfife@email.arizona.edu](mailto:tfife@email.arizona.edu)

tuberculin skin test was negative, but the patient was anergic to mumps.

An excisional biopsy of the right temporal lobe revealed lymphoplasmacytic inflammation with noncaseating granulomas, clusters of fibroblasts and histiocytes, and multinucleated giant cells (figure 2). No cultures grew from the specimen. Antimicrobial therapy was given empirically; it included ceftriaxone, acyclovir, isoniazid, rifampin, ethambutol, and pyrazinamide.

The patient was also started on dexamethasone at 8 mg twice daily.

At a follow-up appointment 2 months later, the patient had shown improvement in her balance, and a repeat MRI demonstrated a partial resolution of the right temporal lesion. The decision was made to taper the steroids and continue the antimicrobial therapy. However, 2 weeks later (and 7 months after her initial onset of imbalance), the patient returned with complaints of acute amnesia and confusion. She said she woke up feeling that she had “lost one and a half years” of memory. On examination, her attention and registration were good, but her recall was poor. She was completely unaware of the events that had led to her current health situation. She exhibited delusional thinking at times. Prior to her current situation, she had no history of behavioral change or cognitive deficit. Her dizziness had also progressed to the point where she felt unable to sit up. A repeat MRI demonstrated significant progression of the left temporal lesion and a slight enlargement of the area of signal change in the hippocampal area on the right side (figure 1, B). Repeat EEG monitoring revealed generalized slowing and no seizures, but phenytoin was started empirically. Computed tomography (CT) scans of the chest, abdomen, and pelvis were negative. A gallium scan demonstrated focal uptake in the hila of both lungs consistent with sarcoidosis, which had not been evident on chest x-ray and chest CT. The patient was stabilized neurologically with methylprednisolone at 1,000 mg/day for 5 days. She was discharged on prednisone at 60 mg/day.

On outpatient follow-up, rotational and caloric vestibular testing demonstrated severe bilateral loss of peripheral vestibular function. The patient’s hearing remained intact, and no uveitis or periocular sarcoidosis

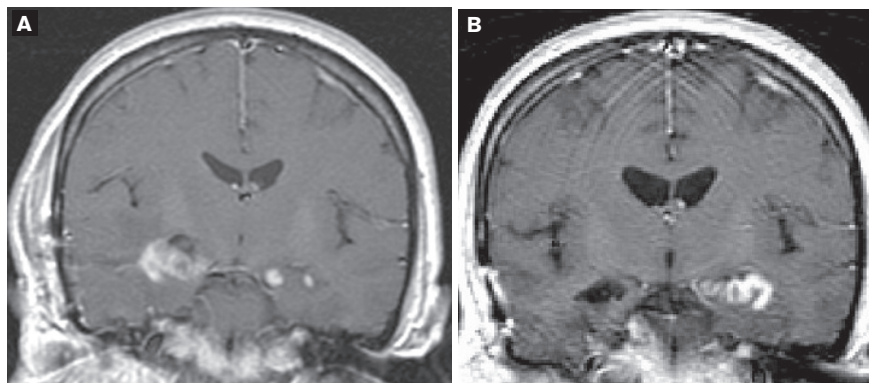


Figure 1. **A:** Coronal T1-weighted MRI 4 months after the onset of symptoms shows gadolinium enhancement of the mesial temporal lobe lesions. **B:** A similar view at 7 months shows postoperative changes in the right temporal lobe.

was observed. Five months later, she died from complications of a myocardial infarction and pulmonary embolism.

#### Discussion

In this case, the initial complaint was of imbalance, which was most likely caused by the progressive bilateral vestibular dysfunction. Bilateral vestibular hypofunction may present without nystagmus, nausea, or vertigo, particularly if the loss of function occurs symmetrically or gradually. Sakakibara et al reported a case of vestibular dysfunction that produced progressive ataxia, but that case also featured some element of communicating hydrocephalus that might have contributed to the ataxia.<sup>5</sup>

Loss of vestibular function has been reported both with<sup>5-10</sup> and without<sup>4</sup> hearing loss. Hearing loss secondary to sarcoidosis is often bilateral and frequently associated with fluctuating hearing. In an extensive review of the literature, Mende and Suchenwirth found hearing loss in 12.2% of patients with neurosarcoidosis and nystagmus in 8.6%.<sup>11</sup> On the other hand, Hybels and Rice found audiovestibular dysfunction to be more common.<sup>12</sup> Colvin’s review of 48 case reports and 2 additional cases found normal hearing in only 1 of 22 patients for whom pure-tone audiometric data were available, suggesting that vestibular loss with spared hearing is quite rare among patients with neurosarcoidosis.<sup>3</sup>

Sarcoidosis-related vestibular dysfunction may occur as a result of vasculitis or granulomatous inflammation of the vestibulocochlear nerves<sup>4,7</sup> and perhaps by direct labyrinthine involvement.<sup>13</sup> Auditory impairment may be caused by granulomatous inflammation of the arachnoid vessels, the cochlear nuclei, vestibulocochlear nerves, or the labyrinth itself.<sup>10</sup> Von Brevern et al found

paroxysmal positional vertical nystagmus with absent horizontal canal vestibular responses.<sup>4</sup> They suggested that selective vestibular dysfunction may result from focal vasculitis. In a case report by Babin et al, temporal bone histology in a patient with deafness showed prominent perivascular lymphocytic infiltration with degeneration of nerve axons and myelin.<sup>14</sup> The authors hypothesized that sarcoidosis in this area

begins as a reversible neuropathy and evolves over time to an irreversible degeneration of neuroepithelium and nerve elements. In our patient, vestibular function never returned, although it is possible that corticosteroids had been administered too late in the clinical course to induce a recovery.

Parenchymal mass lesions have been seen in neurosarcoidosis, and they may mimic gliomas or lymphoma.<sup>15</sup> Our patient developed both an anterograde and temporally graded retrograde amnesia that was clinically and radiographically consistent with the syndrome of bitemporal amnesia.<sup>16</sup> A normal chest x-ray, chest CT, and serum ACE level do not exclude the possibility of neurosarcoidosis.<sup>17,18</sup> A tissue biopsy may be the only means of making the diagnosis in such instances.<sup>19</sup> A gallium scan<sup>20</sup> or whole-body positron-emission tomography<sup>17,21</sup> may also help with the diagnosis if changes are seen in the pulmonary hila or salivary glands, and such imaging may direct the location for a biopsy. Corticosteroids may be used empirically but with caution, and every attempt should be made to confirm a diagnosis because some neurologic manifestations of sarcoidosis may fail to improve with steroids and require more aggressive immunomodulating drugs.<sup>22</sup>

## References

1. Stern BJ, Krumholz A, Johns C, et al. Sarcoidosis and its neurological manifestations. *Arch Neurol* 1985;42(9):909-17.
2. Delaney P. Neurologic manifestations in sarcoidosis: Review of the literature, with a report of 23 cases. *Ann Intern Med* 1977;87(3):336-45.
3. Colvin IB. Audiovestibular manifestations of sarcoidosis: A review of the literature. *Laryngoscope* 2006;116(1):75-82.
4. von Brevern M, Lempert T, Bronstein AM, Kocen R. Selective vestibular damage in neurosarcoidosis. *Ann Neurol* 1997;42(1):117-20.
5. Sakakibara R, Hattori T, Uchiyama T, Yamanishi T. Micturitional disturbance in a patient with neurosarcoidosis. *NeuroUrol Urodyn* 2000;19(3):273-7.

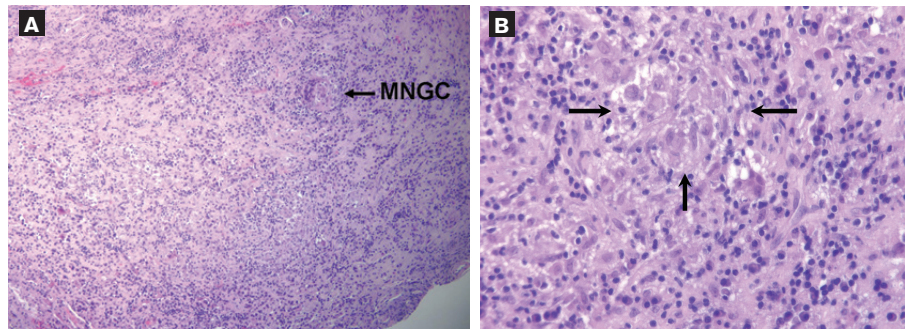


Figure 2. **A:** The histologic section from the right temporal lobe biopsy demonstrates non-necrotizing granulomatous inflammation consisting of nodular foci of numerous histiocytes, lymphocytes, and plasma cells. A multinucleated giant cell (MNGC) is also seen (DAB and hematoxylin, original magnification  $\times 100$ ). **B:** At higher power, a noncaseating granuloma (arrows) demonstrates mononuclear histiocytes admixed with an MNGC (DAB and hematoxylin, original magnification  $\times 400$ ).

6. Agari D, Koide R, Kashiyami T, et al. Neurosarcoidosis: A treatable cause of vestibular dysfunction. *Lancet* 2007;369(9564):878.
7. Garcia Berrocal JR, Trinidad A, Vargas JA, et al. Sudden hearing loss and uveitis as a form of presentation of neurosarcoidosis [in Spanish]. *Acta Otorrinolaryngol Esp* 1998;49(6):488-90.
8. Sugaya F, Shijubo N, Takahashi H, Abe S. Sudden hearing loss as the initial manifestation of neurosarcoidosis. *Sarcoidosis Vasc Diffuse Lung Dis* 1996;13(1):54-6.
9. Sakakibara R, Nakajima M, Hirayama K, Yagihashi M. Psychoneurological symptoms and raised angiotensin-converting enzyme in cerebrospinal fluid in a patient with sarcoidosis beginning in the central nervous system. *Rinsho Shinkeigaku* 1990;30(11):1227-31.
10. Moine A, Frachet B, Van Den Abbeele T, et al. Deafness and sarcoidosis. *Ann Otolaryngol Chir Cervicofac* 1990;107(7):469-73.
11. Mende D, Suchenwirth RM. Neurosarcoidosis. Comparative analysis of the clinical profile based on 537 cases from the world literature up to 1963 and from 1976-1988. *Fortschr Neurol Psychiatr* 1990;58(1):7-18.
12. Hybels RL, Rice DH. Neuro-otologic manifestations of sarcoidosis. *Laryngoscope* 1976;86(12):1873-8.
13. Avilés Mañoso P, Juan Ivars C, Portell Soriano M, Ramos Fernández J. Neurosarcoidosis. Sensorineural hearing loss. *Acta Otorrinolaryngol Esp* 1997;48(3):229-31.
14. Babin RW, Liu C, Aschenbrener C. Histopathology of neurosensory deafness in sarcoidosis. *Ann Otol Rhinol Laryngol* 1984;93(4 Pt 1):389-93.
15. Serès C, Jarnier D, Cohadon F, et al. An unusual form of neurosarcoidosis isolated in association with a tumoral lesion, chronic meningitis, hydrocephalus and hypothalamo-hypophyseal involvement [in French]. *Neurochirurgie* 1999;45(3):243-6.
16. Squire LR. The neuropsychology of human memory. *Annu Rev Neurosci* 1982;5:241-73.
17. Dubey N, Miletich RS, Wasay M, et al. Role of fluorodeoxyglucose positron emission tomography in the diagnosis of neurosarcoidosis. *J Neurol Sci* 2002;205(1):77-81.
18. Dale JC, O'Brien JF. Determination of angiotensin-converting enzyme levels in cerebrospinal fluid is not a useful test for the diagnosis of neurosarcoidosis [letter]. *Mayo Clin Proc* 1999;74(5):535.
19. Randeva HS, Davison R, Chamoun V, Bouloux PM. Isolated neurosarcoidosis—a diagnostic enigma: Case report and discussion. *Endocrine* 2002;17(3):241-7.
20. Sharma OP. Neurosarcoidosis: A personal perspective based on the study of 37 patients. *Chest* 1997;112(1):220-8.
21. Aide N, Benayoun M, Kerrou K, et al. Impact of [18F]-fluorodeoxyglucose ([18F]-FDG) imaging in sarcoidosis: Unsuspected neurosarcoidosis discovered by [18F]-FDG PET and early metabolic response to corticosteroid therapy. *Br J Radiol* 2007;80(951):e67-71.
22. Terushkin V, Stern BJ, Judson MA, et al. Neurosarcoidosis: Presentations and management. *Neurologist* 2010;16(1):2-15.